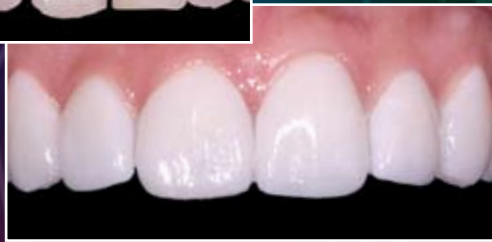
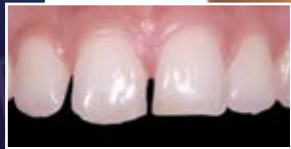
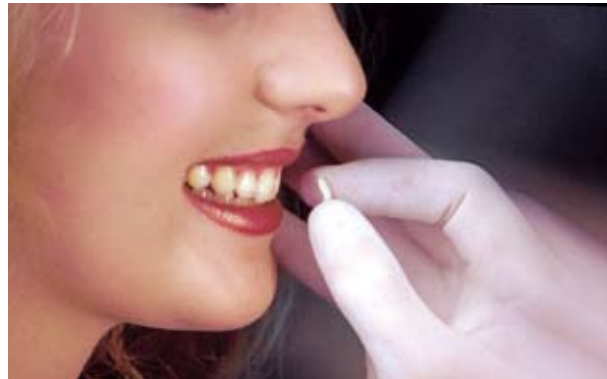
# Beauty Teeth



Jerrika did not like the spaces between her teeth. She did not want to undergo a lot of drilling or other dental work and did not want to have shots of anesthetic. These and other factors made her ideal for a no-prep case, in which there is no work done on the natural teeth. Ultra-thin veneers were made and bonded into place using only veneer cement.

## Improve your smile with Veneers



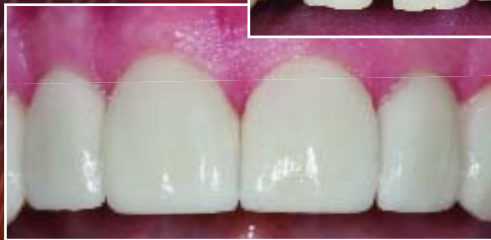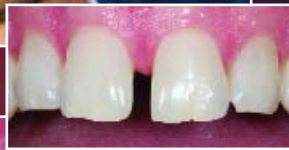No-prep porcelain veneers can give you the beautiful smile you've always wanted with no shots, no drilling and no pain! Your dentist will simply take impressions of your teeth, and the lab will fabricate razor-thin veneers to be placed on top of your natural teeth. No-prep veneers can be used to close spaces between teeth, reshape chipped or worn teeth, or whiten discolored smiles. Your dentist will determine if minimal- or no-prep veneers are right for you. If you are a candidate, your smile makeover can be completed in as few as two appointments.

## PORCELAIN VENEERS

### The Beauty of Veneers

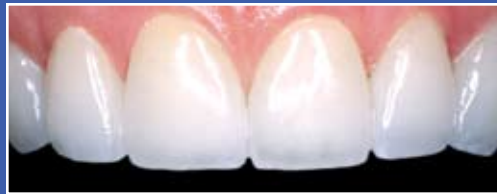
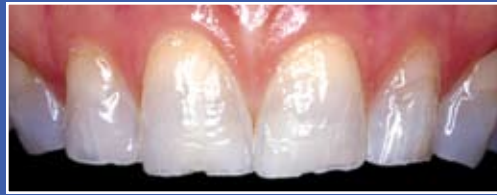
## Close Spaces

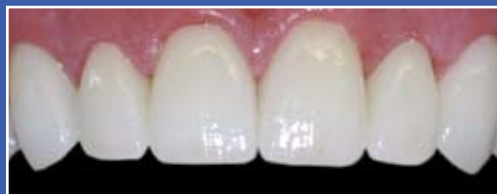
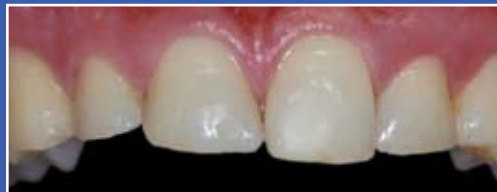
Robert had a large space in the middle of his smile. His teeth were also chipped at the edges. His dentist decided he would be a good candidate for no-prep veneers. This means he did not have to endure any shots, drilling or pain to correct his smile. The veneers were simply bonded into place, on top of his natural teeth. He was extremely happy with his new smile.

## Reshape Teeth

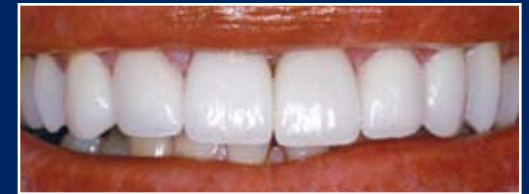
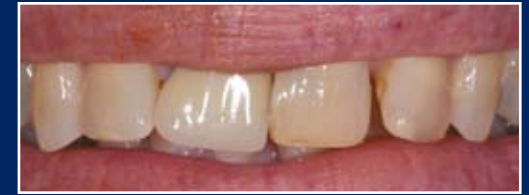
This 51-year-old female patient had problems with grinding, which caused excessive wear on her front teeth. Also, the surfaces of her teeth were rough and irregular, making them prone to staining.

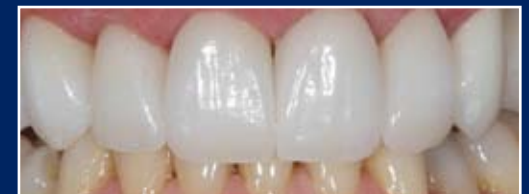
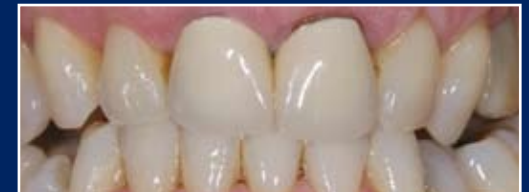
This 39-year-old male was concerned that his two front teeth were different sizes. He also wanted to address his arch alignment problems. It was decided that his teeth needed to be worked on before veneers could be placed.

## Fix Stained Teeth



This 43-year-old wanted to change the shade and alignment of her smile. Veneers were needed on the bicuspids and first molars to correct the alignment and create a pleasing smile.



This 33-year-old patient was dissatisfied with his smile. His chief complaint was the opaque porcelain crowns on his front two teeth. The patient also wanted to replace his old composites and correct his arch problems.